

## CLINICAL EVALUATION OF ROOT END RESECTION BEVEL IN PERIAPICAL SURGERY

Marina Kacarska

Faculty of Dentistry, Department of Oral Surgery, University Ss. Cyril and Methodius, Skopje

**Corresponding author:** Marina Kacarska, Address: Vodnjanska b.b, Skopje, e-mail: marina\_kacarska@yahoo.com

### ABSTRACT

Root end resections play an important role in the success of periapical surgery. Beveling of the root end resections can vary significantly depending on the surgical technique, the root and canal morphology.

The intention of this article was to clinically assess the root resections bevels and to estimate their relation to applied periapical surgeries.

A prospective clinical study consisted of sixty periapical surgeries performed on teeth with chronic periapical lesions. Thirty periapical surgeries were performed in a conventional manner, while thirty were contemporary ultrasonic surgeries. Following the completion of strictly planned and performed intraoperative procedures, the resection bevels were assessed. To obtain the real bevel angles a compass was used. Root resections were significantly less beveled in all teeth operated with contemporary ultrasonic surgery, with mean values between 2.1° to 7.8°. The number of roots and their dilacerations didn't influence the root resection bevel. For comparison, root resections were significantly beveled in all conventionally operated teeth, with mean values of 46°. Due to the technical limitations of the conventional periapical surgery, mandibular premolars were exclusively operated with ultrasonic periapical surgery, with mean values of resection bevel not exceeding 20.7°. Significantly lesser resection bevel associated with ultrasonic periapical surgery contributes to root preservation and favorable surgical outcome.

**Key words:** periapical surgery, root end resection and bevel

### INTRODUCTION

Root end resections are an important aspect of the periapical surgery. The root end is resected in order to identify the root canal and provide access to the source of infection (1). A root resection of 2-3 mm eliminates an apical area with the highest incidence of accessory canals (2) and exposes the root surface within reach of visual inspection and further instrumentation. The apex of most teeth contains multiple foramina and by removing the apical 2-3 mm of the root most of these can be removed (3) but care must be taken not to compromise the crown-to-root length ratio.

Historically, resection and beveling was carried out in order to improve access to the root canal for preparation with a round bur (4). The conventional (bur) type of periapical surgery is virtually unfeasible if root resections are not beveled, resulting in steeper

root resections (approximately 45°) (5). Beveling exposes dentinal tubules, which can allow the leakage of bacterial byproducts and irritants from the root canal past the root end filling (6,7). Gilheany P et al. (8) in their research confirmed a positive correlation between steeper root resections and increased apical permeability due to the exposed dentinal tubules. The least apical permeability was noted in cases with horizontal root resections (marked at 0°). Increased apical permeability was additionally emphasized in periapical surgeries performed on teeth with failed endodontic treatment. The results of the spectrophotometric analysis of a dye penetration in the resected root surfaces performed by Ichescu WR et al. (9) confirmed an increased apical permeability in the endodontically treated teeth in comparison with those that were not.

Apart from the steeper root resections, conventional retropreparations fail to coincide with an axial root inclination (10).

The current biological evidence and the advances in the surgical techniques suggest reduction of the root resection bevel. The root is therefore resected perpendicular to the root canal to reduce the number of exposed dentinal tubules (11).

Horizontal or near horizontal root resections can be maintained exclusively when ultrasonic periapical surgery is performed. This contemporary surgical alternative was first introduced by Carr GB (12) in 1992. Ultrasonic armamentarium consists of miniature 90° angled surgical retrotips which eliminate the need for steep resections and great osteotomies. When used in conjunction with visual enhancements this surgical technique necessitates an almost perpendicular root resection. Most of the studies with concern to the subject of root resection bevel and periapical surgery were performed in laboratory environment on extracted teeth. Therefore our goal was to clinically assess the root resections bevel and to estimate their relation with different methods of periapical surgery.

## MATERIAL AND METHODS

**Study design:** the prospective clinical study consisted of sixty maxillary and mandibular teeth with periapical inflammatory lesions. Thirty teeth were subjected to periapical surgery with conventional retrograde approach, while the rest were treated with contemporary ultrasonic periapical surgery. After the preliminary examinations, the surgical field in every case was anesthetized with submucosal infiltration of 2% scandonest with adrenaline (mepivacaine hydrochloride, Septodont).

All surgeries were performed by the same surgeon. Various full-thickness mucoperiosteal flaps were used depending on the teeth location and the extension of the periapical pathology. After elevat-

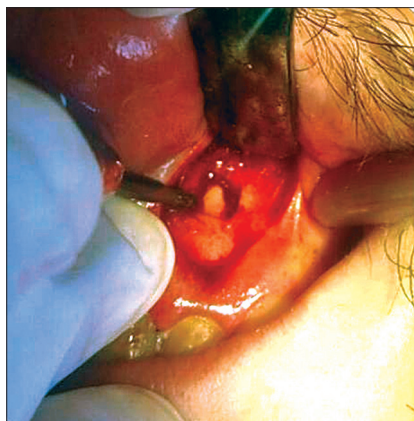
ing the flap, the bone was removed from the apical area to gain access to the lesion and root end. The surgical debridement of the cortical and cancellous bone was performed with a bur and sharp spoon excavator. To prevent the bone dehydration, the area was intermittently rinsed with saline solution during the entire surgical procedure. After the apical root exposure, root end resections were executed with a straight handpiece and a fissure bur (Figure 1).

Conventional periapical surgeries were carried out with small reverse conical burs. (Figure 2). Ultrasonic periapical surgeries were executed with diamond coated (dc) retrotips (source EMS - Nyon Switzerland) (Figure 3). The root bevel was determined by the need for access and visualization to complete the root-end preparation and filling. Following the completion of the strictly planned and performed intraoperative procedures, the bevel angles were assessed.

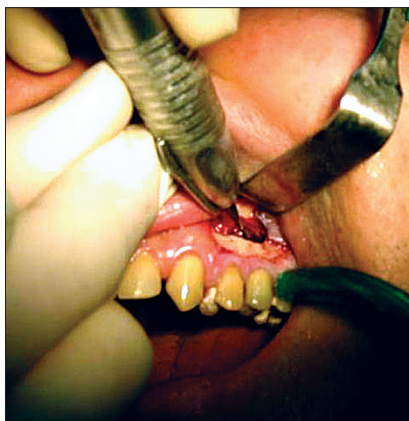
Descriptive statistics (with mean values and percentages) and Mann Whitney U test were used to present the study results.

## RESULTS

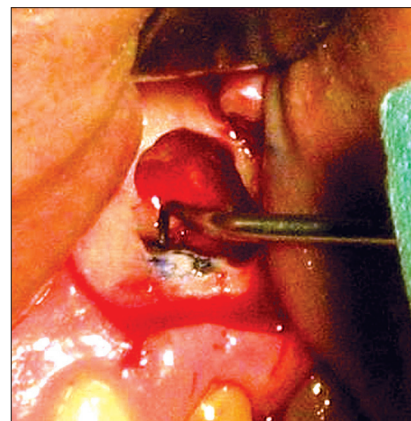
Fifty four teeth (73.3%) underwent periapical surgery due to unsuccessful endodontic treatment. A preoperative radiographic evaluation of the endodontic treatments was presented in Table 1. A satisfied endodontic treatment was evident only in 6.8% of the cases. The rest of the subjects demonstrated radiological features of unsuccessful endodontic treatment, such as: inconsistent root canal filling (11.4%); unfilled 2mm of the root canal (40.9 %); unfilled 2mm of the root canal with external root resorption (4.5%); unfilled apical portion of the root canal (27.3%); overfilled root canals (2.2%) and perforated root canals in the middle section (via falsa) (6.8%).



**Figure 1.**  
Root end resection



**Figure 1.**  
Conventional periapical surgery



**Figure 3.**  
Ultrasonic periapical surgery

**Table 1.** Distribution of operated teeth according to preoperative radiographic evaluation of the endodontic treatment (N=44)

Radiographic evaluation	Number of teeth	%
satisfying root canal filling	3	6.8
root canal with inconsistent canal filling	5	11.4
root canal with unfilled apical 2mm	18	40.9
root canal with unfilled apical 2mm and external resorption	2	4.5
root canal with unfilled apical portion	12	27.3
overfilled root canal	1	2.2
root canal perforated in middle section	3	6.8
<b>Total</b>	<b>44</b>	<b>100</b>

**Table 2.** Distribution of re-operated teeth according to radiographic evaluation of the surgical treatment (N=16)

Radiographic evaluation	Number of teeth	%
correct periapical surgery	2	12.5
unsatisfying periapical surgery with unsealed apical 2 mm	2	12.5
unsatisfying periapical surgery with unsealed apical 4 mm	3	18.75
unsatisfying periapical surgery with unsealed apical third	3	18.75
unsatisfying periapical surgery with inconsistent canal filling	3	18.75
unsatisfying periapical surgery with uncompleted root resections	3	18.75
<b>Total</b>	<b>16</b>	<b>100</b>

**Table 3.** Mean values of root resection bevel in operated teeth according to the morphological classification and surgical technique

Morphological group	Conventional periapical surgery		Ultrasonic periapical surgery	
	root resection bevel (mean value)	sd	root resection bevel (mean value)	sd
MCI	31.0°	4.3°	2.1°	1.1°
MLI	35.0°	4.0°	3.8°	2.7°
MK	36.0°	5.5°	2.3°	1.2°
MP	41.0°	4.4°	7.8°	6.9°
MdI	36.0°	1.4°	19.0°	0.0°
MdP	/	/	20.7°	8.1°

MCI – maxillary central incisors MK- maxillary canines; MLI – maxillary lateral incisors MP – maxillary premolars  
MdI- mandibular incisors; MdP- mandibular premolars

Sixteen teeth (26.7%) were re-operated. Preoperative radiographic evaluation of primary surgeries are presented on table 2. Periapical surgeries were correct in 12.5%. The rest were unsatisfying with: unsealed apical 2 mm (12.5%); unsealed apical 4 mm (18.75%), unsealed apical third (18.75%); inconsistent canal filling (18.75%) and uncompleted root resection in 12.5% of the cases.

The mean values of root resection in relation to the periapical surgeries assessed for every morphological group of operated teeth are presented in Table 3.

The root resections in ultrasonically performed periapical surgeries were significantly less beveled with average values ranging from 2.1° to 7.8°. The number of roots and their dilacerations didn't increase the root resection bevel.

Quite the opposite the conventional periapical surgeries were performed with significantly higher root bevel, with mean value of 46°. Due to the technical limitations of the conventional surgery mandibular premolars were exclusively operated with ultrasonic technique with mean value of root resections of 20.7°.

The statistical Mann Whitney U Test analysis revealed significant differences between the mean values of root resection bevel for two methods of periapical surgery for all groups of operated teeth (Table 4).

**Table 4.** Mann Whitney U Test between mean values of root bevel in regard to surgical methods

Operated teeth	Statistical significance
MCI	p = 0.0011
MLI	p = 0.0014
MK	p = 0.0339
MP	p = 0.0022
MdI	p = 0.0021

## DISCUSSION

In cases of endodontic failure the periapical surgery should be restricted to cases in which a non-surgical approach is impossible or has failed (13,14). When an improper or defective root canal filling is the cause of endodontic failure, and the root canal is coronary accessible and negotiable,

surgical treatment is not considered the treatment of choice (15). The majority of teeth included in this study had periapical lesions associated with failed endodontic treatment (Table 1). The periapical radiographs revealed that periapical lesions correlated with unfilled 2mm of the root canal-s in 40.9 %, and unfilled apical portion of the canal in 27.3% of the cases. Endodontic retreatment was considered unfeasible because the teeth in question had either intra canal posts or were covered with porcelain prosthetic restorations. Subsequently periapical surgery with retrograde approach was a treatment of choice. For cases with overfilled root canals (2.2%) and root perforations as a result of procedural errors (6.8%) periapical and periradicular surgeries were the treatment solution.

Periapical re-surgeries were performed in teeth with periapical lesions associated with unsuccessful surgical treatment (26.7%). The criteria for failure include clinical signs or symptoms, and radiographic evidence of uncertain or unsatisfactory healing. The radiological evidence of unsuccessful periapical surgery were continual periapical radiolucencies correlated with unsealed apical 4 mm (18.75%), unsealed apical third (18.75%), inconsistent canal filling (18.75%) and uncompleted root resection in 12.5% of the cases (Table 2).

Periapical surgery can be performed using conventional or modern techniques. Conventional periapical surgery is executed with a small bur that hinders the surgical access to the apical canal system, unless the root resection is steeper.

The introduction of loupes, ultrasonics, and compatible root-end filling materials has made modern periapical surgery more predictable, and the success rates are now high (16,17,18). The current microsurgical techniques permit precise performance of the surgical procedures, thus eliminating the disadvantages of the traditional periapical surgery. Contemporary ultrasonic surgery is performed with miniature 90° angled retrotips that enable perpendicular access on the minimally resected root surface.

Periapical surgery consists of surgical debridement of pathologic periapical tissue, root-end resection, root-end cavity preparation and root-end filling to seal the root canal.

Root end resection is an important step. The correct root resection enables visual and instrumental approach to the entire resected root surface without compromising the root length and the integrity of the vestibular lamina. Kim and Kratchman suggest that at least 3 mm of the root-end must be removed to reduce 98% of apical ramifications and 93% of lateral canals (19). Using a water-cooled fissure bur,

an apical resection about 3 mm from the apex is performed, using a limited bevel.

Kratchman SI. (20), Rubinstein R. et al (21); Von Arx T. et al. (22), Gilheany P. et al. (8), Kim S. et al. (5) recommended root resections with a shallow bevel, not more than 10° in order to reveal the entire canal system with simultaneous preservation of the vestibular lamina.

In their investigation performed on extracted teeth, Melhaff et al. recorded significantly higher values for the resection angle in periapical surgeries performed with bur (35.1° mean value) versus ultrasonic surgeries, where the average resection bevel had amounted value to 16.0° (23).

According to Petrovic V. et al. (24) in certain cases root resection can be even steeper (45° and more), but such circumstances increase the risk of incomplete elimination of apical ramifications.

If the root resection is steeper, removal of the apical ramifications will be partial, larger amount of dentinal tubules will be exposed and the surgical outcome will be challenged.

Vertucci RJ. et al. (25) consider exposed dentinal tubules to present a potential vector for apical permeability.

The results from our clinical study displayed significant correlation between the root resection bevel and the applied surgical techniques.

The mean values of root resections in conventional periapical surgeries ranged from 31° for maxillary central incisors (MCI) to 41° for maxillary premolars (MP).

As expected, the mean values of root resections in ultrasonic periapical surgeries were lesser, ranging from 2.1° for maxillary central incisors (MCI) to 7.8° for maxillary premolars (MP). Due to the technical limitations of the conventional periapical surgery, mandibular premolars were exclusively operated with ultrasound technique with mean root resection value of 20°.

Our findings were in accordance with the recommendations of Kim S. (3), Gilheany P. et al. (11), Melhaff D. et al. (23), Kratchman SI. (20).

There is no biological justification for a steep bevel angle. It was strictly for the convenience of the surgeons for apex identification and for the subsequent apical preparation (13,14). In fact, beveling causes significant damage to the very tissue structures that the surgery is designed to save, i.e. buccal bone and root. By diagonal resection, the result of steep beveling, the buccal bone is removed along with a large area of the root causing, in effect, a large osteotomy. Furthermore, beveling frequently misses the lingually positioned apex, causes elongation of



the canal and reduction of the root diameter, thereby weakening it (26, 27, 28).

Root resection beveling also influences the depth of the retro-preparation. Ninety degree root resection requires apical preparation with minimal depth of 1mm for quality retro-obturation. The increasing of the root resection bevel requires deepening of the apical cavity Gilheani et al. (8), which is difficult to achieve.

## CONCLUSION

The results from our clinical study revealed that root end resections bevel correlated with periapical surgical techniques. The significantly lower values for the root resections were associated with ultrasonic periapical surgery. Lesser resection bevel preserves the root length, lessens the apical permeability and creates favorable circumstances for superior surgical outcome.

## REFERENCES

1. J.S.Rohdes. Endodontics: Clinical retreatment and surgery. Taylor&Frances UK, © 2006.
2. Gerstein H. Surgical endodontics. In: Laskin DN, editor. Oral and maxillofacial surgery. Vol 2. St. Louis (MO): Mosby; 1985.
3. Kim S, Pecora G, Rubinstein RA. *Colour atlas of microsurgery in endodontics*. London: WB Saunders; 2001.
4. Rud J, Andreasen JO. Operative procedures in periapical surgery with contemporaneous root filling. *International Journal of Oral Surgery* 1972; 1: 297-310.
5. Kim S: Principles of endodontic microsurgery. *Dent Clin of North America* 1997, 41 (3) 481-47
6. hong BS, Pitt Ford TR, Kariyawasam SP. Tissue response to potential root-end filling materials in infected root canals. *International Endodontic Journal* 1997; **30**: 102-114.
7. Tidmarsh BG, Arrowsmith Dentinal tubules at the root ends of apicected teeth: a scanning electron microscopic study. *International Endodontic Journal* 1989; **22**: 184-189.
8. Gilheany P, Figdor D, Tyas M: Apical dentin permeability and micro leakage associated with root end resection and retrograde filling. *J Endod* 1994; 20:22-26
9. Ichesco WR, Ellison RL, Corcoran JR, Krause DC. A spectrophotometric analysis of dentinal leakage in the resected root. *J Endod* 1986;12:129.
10. Wuchenich G, Meadows D, Torabinejad M: A comparison between two root end preparation techniques in human cadavers. *J of Endod* 1994;20(6):279-82.
11. Gilheany PA, Figdor D, Tyas MJ. Apical dentin permeability and microleakage associated with root end resection and retrograde filling. *Journal of Endodontics* 1994; 20: 22-26.
12. Carr GB.: Ultrasonic root end preparation. *Dental Clinics of North America*;1997 41(3) 541-54.
13. Gutmann JL, Harrison JW (1985) Posterior endodontic surgery: anatomical considerations and clinical techniques. *Int Endod J* 18, 8-34.
14. Danin J, Strömberg T, Forsgren H, Linder LE, Ramsköld LO (1996) Clinical management of nonhealing periradicular pathosis. Surgery versus endodontic retreatment. *Oral Surg Oral Med Oral Pathol Oral Radiol Endod* 82, 213-217.
15. Abramovitz I, Better H, Shacham A, Shlomi B, Metzger Z (2002). Case selection for apical surgery: a retrospective evaluation of associated factors and rational. *J Endod* 28, 527-530.
16. Carr GB (1992) Microscopes in endodontics. *J Calif Dent Assoc* 20, 55-61.
17. Torabinejad M, Watson TF, Pitt Ford TR (1993) Sealing ability of a mineral trioxide aggregate when used as a root end filling material. *J Endod* 19, 591-595.
18. Rubinstein RA, Kim S (1999) Short-term observation of the results of endodontic surgery with the use of a surgical operation microscope and super-EBA as root-end filling material. *J Endod* 25, 43-48.
19. Frank A, Simon J, Abou-Rass M, Glick D. Clinical and surgical endodontics: concepts in practice. Philadelphia: JB Lippincott; 1983.
20. Kratchman S. I: Endodontic Microsurgery. *Compendium of continuing education in dentistry* 2007;25;20-26.
21. Rubinstein RA, Kim S: Long-term follow-up of cases considered healed one year after apical microsurgery. *J Endod.* 2002; 28:378-383.
22. Von Arx T, Kurt B: Root-end cavity preparation after apicoectomy using a new type of sonic diamond surfaced retrotip: a 1-year follow up study. *J Oral Maxillofac Surg* 1999, Jun;57(6);656-61
23. Mehlhaff DS, Marshall JG, Baumgartner JC: Comparison of ultrasonic and high speed bur root end preparations using bilaterally matched teeth. *J of Endod* 1997(23),448-52.

24. Petrovic V, Colic S: Periapikalne lezije 2001. 81-87;105-115
25. Vertucci RJ, Beatty RG. Apical leakage associated with retrofillings techniques: a dye study. J Endod 1986;12:331.
26. Kim S, Pecora G, Rubinstein R. Comparison of traditional and microsurgery in endodontics. In: Kim S, Pecora G, Rubinstein R, eds. Color atlas of microsurgery in endodontics. Philadelphia: W.B. Saunders, 2001:5–11.
27. Carr GB. Surgical endodontics. In: Cohen S, Burns R, eds. Pathways of the pulp, 6<sup>th</sup> ed. St Louis: Mosby, 1994:531.
28. Kim S. Endodontic microsurgery. In: Cohen S, Burns R, eds. Pathways of the pulp, 8<sup>th</sup> ed. St Louis: Mosby, 2002:683–721.

## Резиме

### КЛИНИЧКА ЕВАЛУАЦИЈА НА ЗАКОСУВАЊЕТО НА КОРЕНСКИТЕ РЕСЕКЦИИ ВО ПЕРИАПИКАЛНАТА ХИРУРГИЈА

Марина Кацарска

Стоматолошки факултет, Катедра за орална хирургија, Универзитет „Св. Кирил и Методиј“, Скопје

#### Апстракт

Коренските ресекции играат важна улога во периапикалната хирургија. Закосувањето со кое тие се изведуваат може значително да варира во зависност од оперативните техники, коренската и канална морфологија.

Целта на овој труд беше да се направи клиничка евалуација на закосувањето на коренските ресекции и да се утврди нивната корелација со применетите оперативни техники.

Проспективната клиничка студија интегрираше шеесет индицирани периапикални хируршки процедури на заби со хронични периапикални лезии. Триесет периапикални хируршки интервенции беа со конвенционален приод, додека другите беа изведени со современа ултрасонична метода. По целосното финализирање на сите интраоперативни процедури, закосувањето на коренските ресекции беше евидентирано поединечно, за секој случај, со примена на шестар и агломер. Коренски ресекции со значително помало закосување, со средна вредност помеѓу 2,1° и 7,8°, беа евидентирани кај сите заби оперирани со современата ултрасонична хируршка техника. Бројот на корените и нивната дивергентност не влијаеја на закосувањето на коренските ресекции. Спротивно, значително закосени беа коренските ресекции евидентирани кај сите конвенционално оперирани заби, со средна вредност од 46°. Поради лимитираните перформанси на конвенционалната периапикална хирургија, мандибуларните премолари беа оперирани исклучиво со ултрасонична техника, со средни вредности на коренските ресекции не поголеми од 20,7°. Значително помалото закосување на коренските ресекции, евидентирано за ултрасоничната хирургија, придонесува кон презервација на коренскиот супстрат и кон подобар оперативен исход.

**Клучни зборови:** периапикална хирургија, коренска ресекција и закосување